



Case Report

# Focal muscle vibrations improve swallowing in persistent dysphagia after traumatic brain injury: A case report

Chiara Ciritella<sup>1</sup>, Stefania Spina<sup>1</sup>, Nicoletta Cinone<sup>1</sup>, Mario Pio Giordano<sup>2</sup>, Salvatore Facciorusso<sup>3</sup>, Andrea Santamato<sup>1</sup>

<sup>1</sup>Spasticity and Movement Disorders Unit, Physical Medicine and Rehabilitation Unit, Policlinico Riuniti and University of Foggia, Viale Pinto, Foggia, Italy

<sup>2</sup>Department of Radiology, University of Foggia, Foggia, Italy

<sup>3</sup>Villa Beretta Rehabilitation Center, Valduce Hospital, Costa Masnaga, Lecco, Italy

## ABSTRACT

Dysphagia is a common complication following traumatic brain injury (TBI), and it is related to an increased risk of malnutrition, pneumonia, and poor prognosis. In this article, we present a case of TBI with persistent dysphagia treated with focal muscle vibration. A 100 Hz and 50 Hz vibratory stimuli were applied over the suprahyoid muscles and tongue (30 min twice a day; five days a week; for a total of four weeks) in addition to the conventional therapy to quickly recover swallowing and avoid the possibility of permanent deficits. In conclusion, this case highlights a novel therapeutic approach for persistent dysphagia in TBI, which should be considered in the management of dysphagia.

**Keywords:** Dysphagia, focal muscle vibration, traumatic brain injury.

Dysphagia is a common symptom in many neurological disorders, such as stroke, traumatic brain injury (TBI), amyotrophic lateral sclerosis, myasthenia gravis, and Parkinson's disease. Swallowing impairments are frequent in patients with severe TBI; among TBI patients in rehabilitation, the incidence of impaired oral feeding reportedly ranges between 25 and 93%.<sup>[1]</sup> Dysphagia may lead to several complications such as aspiration pneumonia, malnutrition, dehydration, and is a marker of poor prognosis, persistent disability, prolonged hospital admission, reduced likelihood of positive rehabilitation outcomes, and mortality.<sup>[2]</sup>

Currently, there are different therapeutic options for the treatment of oropharyngeal dysphagia including patient-specific variation in dietary texture, postural changes/compensatory maneuvers, electrical neuromuscular stimulation, thermal-tactile stimulation, strengthening exercises, lingual/larynx-motional exercises, and cortical neuromodulation.<sup>[3]</sup> In recent years, focal muscle

vibration has been proposed as a novel method of upregulating swallowing rates both in healthy individuals and in patients with dysphagia.<sup>[4,5]</sup> Moreover, a recent review has demonstrated that focal muscle vibration is safe and well-tolerated in individuals with neurological disorders.<sup>[6]</sup> Mechanical vibrations provide an exteroceptive and a proprioceptive stimulus reaching the upper centers of the central nervous system.<sup>[4,7]</sup> We hypothesize that the addition of focal vibrations after an incomplete recovery following a period of rehabilitation with conventional restitution techniques may further improve swallowing function. To the best of our knowledge, there are no studies demonstrating that mechanical vibration added to conventional therapy may improve swallowing function in TBI patients.

In this article, we discuss beneficial effects of adding focal muscle vibration to a conventional rehabilitation treatment in a male patient affected by dysphagia due to severe TBI.

**Corresponding author:** Stefania Spina, MD. Spasticity and Movement Disorders Unit, Physical Medicine and Rehabilitation Section Policlinico Riuniti and University of Foggia Viale Pinto, 71100, Foggia, Italy.

**E-mail:** [spinastefania.ss@gmail.com](mailto:spinastefania.ss@gmail.com)

**Received:** July 08, 2022 **Accepted:** March 10, 2023 **Published online:** May 03, 2023

**Cite this article as:** Ciritella C, Spina S, Cinone N, Giordano MP, Facciorusso S, Santamato A. Focal muscle vibrations improve swallowing in persistent dysphagia after traumatic brain injury: A case report. Turk J Phys Med Rehab 2024;70(2):274-278. doi: 10.5606/tftrd.2023.11351.



This is an open access article under the terms of the Creative Commons Attribution-NonCommercial License, which permits use, distribution and reproduction in any medium, provided the original work is properly cited and is not used for commercial purposes (<http://creativecommons.org/licenses/by-nc/4.0/>).

## CASE REPORT

A 38-year-old Caucasian male patient was admitted with a medical history of severe TBI and abdominal and thoracic trauma due to a car accident. He was admitted to the intensive care unit (ICU) with an Injury Severity Score (ISS) of 48 out of 75 (i.e., severe head injury, severe chest injury, severe abdominal injury). An urgent cranial computed tomography (CT) showed parietal bone fracture, brain edema, and no active parenchymal lesions. A neurological examination was carried out to explore motor and cognitive impairments. The cognitive and behavioral assessment showed a level VII at the Rancho Los Amigos Revised Scale (RLAS-R) Level of Cognitive Functioning Scale (LCFS).<sup>[8]</sup> At the time of admission, no motor impairment was observed.

The patient was mechanically ventilated through an endotracheal tube for seven days and artificially supported throughout parenteral nutrition. During the ICU stay, he underwent cranial magnetic resonance imaging which showed the absence of focal lesions or other relevant alterations.

After two weeks, the patient was transferred to the General Surgery Department for the management of the abdominal trauma. A baseline bedside dysphagia assessment was consulted by a speech and language therapist (SLT), which revealed mild dysphonia, deviation to the left side of his tongue, and an impaired left palatal elevation. There was no oropharyngeal sensitivity impairment and the gag reflex was present on both sides. Finally, no dysarthria, facial palsy, or buccofacial apraxia was present.

The Gugging Swallowing Screen (GSS) was performed to assess the severity of aspiration risk:<sup>[9]</sup> the patient reached a total score of 4 out of 20 due to the inability to manage oral secretion. The screening test indicated the presence of severe dysphagia with a high risk of aspiration and the need to execute an instrumental assessment of swallowing function. Therefore, a fiberoptic endoscopic evaluation of swallowing (FEES) was conducted. The FEES is a well-tolerated and safe examination in which a flexible nasopharyngolaryngoscope is introduced transnasally into the pharynx for direct visualization of the swallowing act. It is used to identify pathological movement patterns and evaluate the effectiveness and safety of the swallowing process. During FEES, the Pooling Score (P-score) was used to quantify the severity of swallowing disorder based on the material present in the hypopharynx and larynx, prior and/or following

to swallowing. This score (min 4 - max 11) is the sum of three different variables: site (1-4), amount (1-3), and management (2-4).<sup>[10]</sup> In our case, the P-score was 11 (severe dysphagia), indicating the presence of a maximum amount of pooling at the level of vocal cord and more than five dry swallows or inefficient attempts of removal and a diagnosis of severe dysphagia. Moreover, during the procedure, the specialist detected unilateral left tongue weakness and a complete palsy of the left vocal fold.

Secondly, a videofluoroscopy (VFS) with Gastrografin® (Bracco Diagnostics Inc., NJ, USA) was performed to more directly assess the presence and extent of swallow dysfunction. The examination started with a low volume (5 mL bolus) of thin liquid and was interrupted as the patient suddenly presented a sign of impaired safety. The VFS showed a slow flow of contrast medium in the pharynx as for abnormal muscular function with resulting liquid passage in the trachea and left bronchus (Figure 1). In detail, the alterations recorded were as follows:

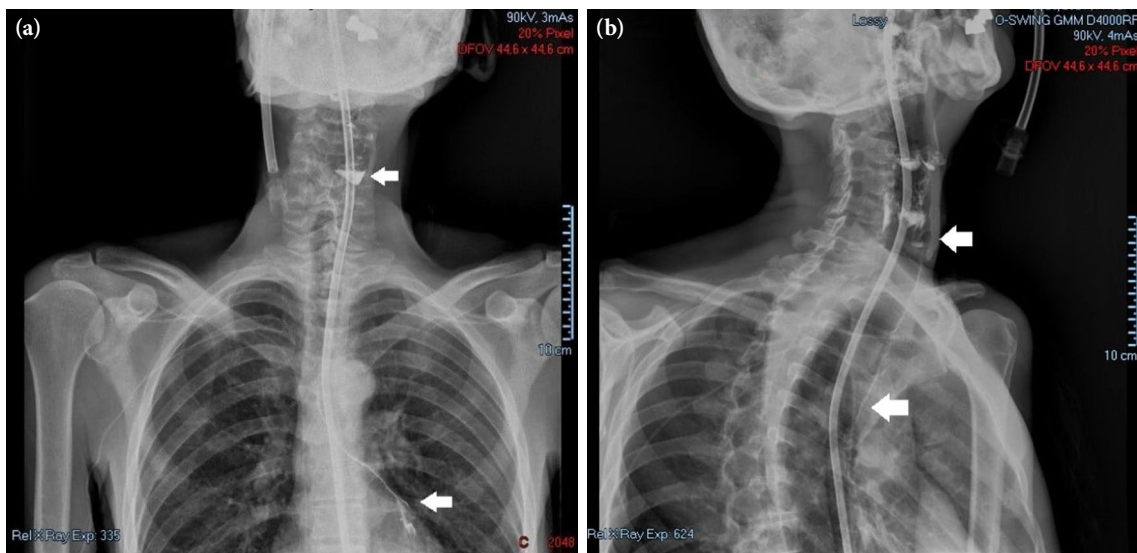
Lateral view oral phase: inefficient tongue movements, moderate delayed bolus transport;

Lateral view pharyngeal phase: absent laryngeal elevation, incomplete epiglottic movement, tracheal penetration, moderate retention; and

Frontal view: unilateral paresis of pharyngeal wall.

Finally, the Functional Oral Intake Scale (FOIS) documented patient's functional levels of oral intake.<sup>[11]</sup> The scale contains seven components: Level 1 through Level 3 relate to varying degrees of non-oral feeding; while Level 4 through Level 7 relate to varying degrees of oral feeding without non-oral supplementation. In our patient, the FOIS score was 1. Consequently, the SLT recommended "nil by mouth" (nothing-per-os) and the patient was fed by enteral feeding via a nasogastric tube (NT).

The patient started a rehabilitation program focused on swallowing recovery based on learning compensation strategy by facilitative posture, proprioception and sensory exercise through different stimulations and techniques such as thermal tactile stimulation, swallowing maneuvers to ensure airway protection prior to and throughout the swallow, specialized exercises to the striated musculature of the tongue, pharynx, and cervical esophagus region, breathing exercises, voice exercises. Six weeks later, the patient was admitted to the Rehabilitation Department and continued the previous training



**Figure 1.** (a) Frontal and (b) lateral projections during videofluoroscopy showing a slow flow of Gastrografin® in the pharynx as for abnormal muscular function with retention in the left piriform sinus and Gastrografin® passage in the trachea and left bronchus (white arrows).

(1 h per day, five days a week). After 10 weeks from the trauma, the patient was re-examined: a second FEES evaluation revealed no improvement (P-score 11) and the FOIS score was 1. Due to persistent severity of dysphagia, the risk of complication still consistent, and risks associated with long-term use of NT, the otolaryngologist addressed the option of a percutaneous endoscopic gastrostomy (PEG) tube placement. Before considering an invasive procedure such as PEG tube placement, the Rehabilitation Team proposed focal vibration as an additional treatment using the NOVAFON Pro Sk2/2 (NOVAFON GmbH, Weinstadt, Germany) device. The device consists of a switch with two levels to adjust the frequency of the vibration produced (50/100 Hz); a handpiece to modify the power of the vibration; spherical and disc-shaped oral heads to stimulate the skin and mucous membranes and an extension clamp. The protocol consisted of three phases of treatment using vibration at 100 Hz frequency during phases I and II. At the beginning, 100 Hz was applied with the oral head on the superior and inferior part of the tongue for 5 min. Then, 100 Hz with an extra oral head was used on the peri-orbicular into and out of the mouth's musculature to increase the tone for 5 min. Finally, 20 min of vibrations at 50 Hz frequency were delivered on suprahyoid muscles with moderate pressure and rotational movements of the device to reduce tone of muscles previously stimulated. The sites of stimulation were selected due to their role as

sensitive organs and their connections with cerebral areas.<sup>[4,12]</sup>

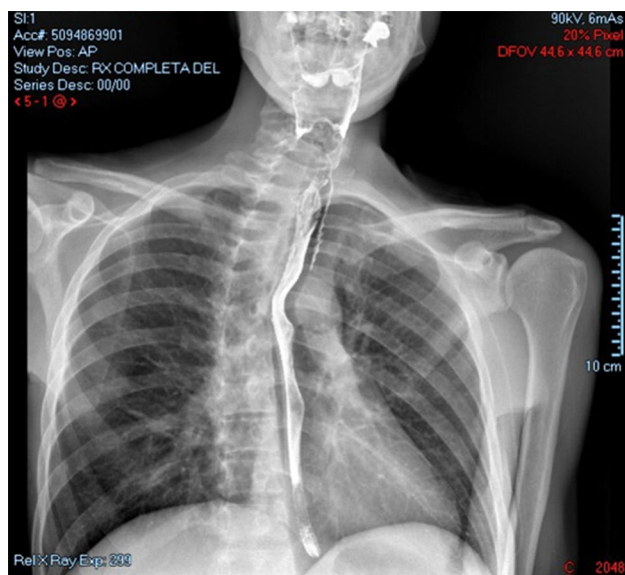
This program was done for four weeks, five times a week, for 30 min twice a day. At the end of the treatment, clinical and instrumental follow-up evaluation were conducted. Accordingly, the P-score showed the complete absence of residue in the pharynx after swallowing and FOIS score increased to 7 from 1. The clinical recovery of swallowing was also confirmed with VFS which showed the absence of the previous contrast medium passage in the trachea and in the left bronchus, and a regular passage of the bolus into the esophagus as a correct muscular function (Figure 2). However, a mild bilateral residual bolus in the vallecular spaces and pyriform sinuses was still present.

At the time of discharge from the hospital, the patient was able to resume full oral feeding without the need for posture adaptation and texture-modified food. Moreover, the PEG tube placement was avoided and the quality of life of the patient was preserved.

## DISCUSSION

In the present report, we describe a case of severe TBI and emphasize that the addition of focal muscle vibrations over suprahyoid muscle allows a better improvement than conventional treatment alone.

It is well recognized that swallowing dysfunction after TBI is largely reversible. Hansen et al.<sup>[13]</sup> reported



**Figure 2.** Frontal projections during videofluoroscopy after the local vibration therapy showing a regular passage of Gastrografin® into esophagus and the absence of the Gastrografin® passage in the trachea and left bronchus.

that 64% of cases recovered to unrestricted diet within 126 days. This is particularly true in patients with mild-to-moderate dysphagia, whereas patients with severe dysphagia hardly make progress.<sup>[13]</sup> However, our case had severe dysphagia and did not improve within the first 12 weeks of treatment. After having applied all the conventional strategies, only a mild improvement could be achieved. The patient showed no improvement at FEES evaluation (P-score 11) and the FOIS score remained unchanged. As a result, the PEG tube placement was recommended as a solution to allow an adequate nutritional support. However, we decided to treat this case by adding a tool that provides focal muscle vibration either on the tongue and the external surface overlying the pharynx and larynx specifically over the suprahyoid muscles and tongue. After four weeks of vibration therapy, the FEES demonstrated the complete absence of residue in the pharynx after swallowing and FOIS increased to 7 from 1.

Mechanical vibrations applied on the surface overlying the target muscles can reach the mechanoreceptors located in the muscle belly and/or its tendon, and can activate the muscle spindles evoking an involuntary reflex contraction called tonic vibration reflex.<sup>[6,14]</sup> The report by Mulheren and Ludlow<sup>[4]</sup> showed that vibration over the larynx increased swallowing and cortical activation for swallowing in six healthy volunteers.

Vibration reaches the upper centers of the central nervous system as both an exteroceptive stimulus and a proprioceptive stimulus,<sup>[15]</sup> inducing changes in cortical activity. In our case, we applied muscle vibration to obtain these effects on the swallowing central pattern generator (CPG) located in the medulla oblongata. The CPG is composed of networks of interneurons that activate groups of motor neurons to generate the task-specific motor pattern of swallowing. It receives sensitive inputs from oral, pharyngeal and laryngeal mucosa, as well as from upper cerebral areas and can modulate swallowing phases. Finally, the two CPGs on both sides organize the coordinate contraction of the bilateral muscles of the oropharyngeal region. It has been demonstrated that vibration likely potentiates the CPG activity for swallowing.<sup>[4]</sup> Moreover, Bordoni et al.<sup>[7]</sup> well described the communication between tongue and body systems. The tongue is a muscular organ rich in sensory, mechanic and taste receptors with a crucial role in swallowing. It has a bilateral representation in the brain that control tongue movements by corticobulbar connections between motor cortex and hypoglossal nuclei. In the light of literature data, we applied mechanical vibration on the tongue, as well.

Finally, the reduction of penetration or aspiration and the presence of residue in the pyriform sinuses and valleculae was confirmed via VFS. Thus, given the described swallowing neurological pathways and the clinically and instrumentally measured improvement, these findings support the potential positive effects of focal vibration in the recovery of dysphagia in patients affected by TBI. However, it should be noted that this report did not control for spontaneous recovery or the effects of other treatments, limiting the ability to definitively conclude that the improvements obtained in dysphagia are solely due to the application of focal muscle vibration. Finally, the results of this case report should not be generalized, although they are valuable as they provide preliminary evidence that may be investigated in future studies with larger sample sizes.

In conclusion, focal muscle vibration is a safe and effective treatment for dysphagia and may be an additional strategy to regain swallowing and reduce the risk of irreversible impairments in TBI. Vibratory stimulation can be used as a sensory input to up-regulate brain networks via mechanoreceptor activation and



improve muscle physiology by activating muscle spindles during dysphagia rehabilitation, assisting swallowing recovery. We consider the possibility of using this treatment for persistent dysphagia after TBI.

**Patient Consent for Publication:** A written informed consent was obtained from patient.

**Data Sharing Statement:** The data that support the findings of this study are available from the corresponding author upon reasonable request.

**Author Contributions:** Idea/concept: C.C., A.S.; Design: C.C., S.S.; Control/supervision: A.S.; Data collection and/or processing: C.C., M.P.G.; Analysis and/or interpretation, literature review, writing the article: S.S., S.F.; Critical review: N.C., A.S.; Materials: M.P.G.

**Conflict of Interest:** The authors declared no conflicts of interest with respect to the authorship and/or publication of this article.

**Funding:** The authors received no financial support for the research and/or authorship of this article.

## REFERENCES

1. Lee WK, Yeom J, Lee WH, Seo HG, Oh BM, Han TR. Characteristics of dysphagia in severe traumatic brain injury patients: A comparison with stroke patients. *Ann Rehabil Med* 2016;40:432-9. doi: 10.5535/arm.2016.40.3.432.
2. Panebianco M, Marchese-Ragona R, Masiero S, Restivo DA. Dysphagia in neurological diseases: A literature review. *Neurol Sci* 2020;41:3067-73. doi: 10.1007/s10072-020-04495-2.
3. Eskildsen SJ, Poulsen I, Jakobsen D, Riberholt CG, Curtis DJ. Scoping review to identify and map non-pharmacological, non-surgical treatments for dysphagia following moderate-to-severe acquired brain injury. *BMJ Open* 2021;11:e053244. doi: 10.1136/bmjopen-2021-053244.
4. Mulheren RW, Ludlow CL. Vibration over the larynx increases swallowing and cortical activation for swallowing. *J Neurophysiol* 2017;118:1698-708. doi: 10.1152/jn.00244.2017.
5. Kamarunas E, Wong SM, Ludlow CL. Laryngeal vibration increases spontaneous swallowing rates in chronic oropharyngeal dysphagia: A proof-of-principle pilot study. *Dysphagia* 2019;34:640-53. doi: 10.1007/s00455-018-9962-z.
6. Murillo N, Valls-Sole J, Vidal J, Opisso E, Medina J, Kumru H. Focal vibration in neurorehabilitation. *Eur J Phys Rehabil Med* 2014;50:231-42.
7. Bordoni B, Morabito B, Mitrano R, Simonelli M, Toccafondi A. The anatomical relationships of the tongue with the body system. *Cureus* 2018;10:e3695. doi: 10.7759/cureus.3695.
8. Lin K, Dulebohn SC. Ranchos Los Amigos. *StatPearls*; 2022.
9. Trapl M, Enderle P, Nowotny M, Teuschl Y, Matz K, Dachenhausen A, et al. Dysphagiabedside screening for acute-stroke patients: The Gugging Swallowing Screen. *Stroke* 2007;38:2948-52. doi: 10.1161/STROKEAHA.107.483933.
10. Farneti D, Fattori B, Nacci A, Mancini V, Simonelli M, Ruoppolo G, et al. The Pooling-score (P-score): Inter- and intra-rater reliability in endoscopic assessment of the severity of dysphagia. *Acta Otorhinolaryngol Ital* 2014;34:105-10.
11. Crary MA, Mann GD, Groher ME. Initial psychometric assessment of a functional oral intake scale for dysphagia in stroke patients. *Arch Phys Med Rehabil* 2005;86:1516-20. doi: 10.1016/j.apmr.2004.11.049.
12. Lowell SY, Poletto CJ, Knorr-Chung BR, Reynolds RC, Simonyan K, Ludlow CL. Sensory stimulation activates both motor and sensory components of the swallowing system. *Neuroimage* 2008;42:285-95. doi: 10.1016/j.neuroimage.2008.04.234.
13. Hansen TS, Engberg AW, Larsen K. Functional oral intake and time to reach unrestricted dieting for patients with traumatic brain injury. *Arch Phys Med Rehabil* 2008;89:1556-62. doi: 10.1016/j.apmr.2007.11.063.
14. Avvantaggiato C, Casale R, Cinone N, Facciorusso S, Turitto A, Stuppiello L, et al. Localized muscle vibration in the treatment of motor impairment and spasticity in post-stroke patients: A systematic review. *Eur J Phys Rehabil Med* 2021;57:44-60. doi: 10.23736/S1973-9087.20.06390-X.
15. Gilman S. Joint position sense and vibration sense: Anatomical organisation and assessment. *J Neurol Neurosurg Psychiatry* 2002;73:473-7. doi: 10.1136/jnnp.73.5.473.