

# Is it necessary to use a sling or abduction pillow sling after superior rotator cuff repair? A preliminary report

İsmail Murad Pepe<sup>1</sup>, Yavuz Şahbat<sup>2</sup>, Emre Çalıřal<sup>3</sup>, Selçuk Yılmaz<sup>4</sup>, İsmet Aslı Topcuođlu<sup>5</sup>, Ayça Aracı<sup>5</sup>, Yıldız Erdođanođlu<sup>6</sup>

<sup>1</sup>Department of Orthopaedic Surgery and Traumatology, Antalya Bilim University, Antalya, Türkiye

<sup>2</sup>Department of Orthopaedic Surgery and Traumatology, Maresal Çakmak Military Hospital, Erzurum, Türkiye

<sup>3</sup>Department of Orthopaedic Surgery and Traumatology, Amasya University Faculty of Medicine, Amasya, Türkiye

<sup>4</sup>Department of Orthopaedic Surgery and Traumatology, Kütahya University Faculty of Medicine, Kütahya, Türkiye

<sup>5</sup>Department of Physiotherapy and Rehabilitation, Alanya Alaaddin Keykubat University, Antalya, Türkiye

<sup>6</sup>Department of Physiotherapy and Rehabilitation, Antalya Bilim University, Antalya, Türkiye

## ABSTRACT

**Objectives:** The study aimed to evaluate the effects of the use of a shoulder sling, shoulder sling with a pillow, or not using a sling on the shoulder functional score and pain levels following arthroscopic rotator cuff tear repair.

**Patients and methods:** This randomized prospective study was performed with 90 patients (49 males, 41 females; mean age: 56.2±12.2 year; range, 33 to 77 years) with a small-to-mid, full-thickness rotator cuff tear between July 2020 and October 2022. All patients underwent arthroscopic double-row repair. The nonsling group wore no sling, the sling group wore a sling, and the abduction pillow sling group wore a sling with an abduction pillow. The same rehabilitation program was performed. The Visual Analog Scale (VAS) score, Constant-Murley scores, and degrees of flexion and abduction were recorded preoperatively, on the 15<sup>th</sup> and 45<sup>th</sup> days, and at three months, six months, and one year.

**Results:** On the 15<sup>th</sup> postoperative day, the VAS score was found to be significantly lower in the nonsling group. On the 45<sup>th</sup> day, the Constant-Murley score was found to be significantly higher in the abduction pillow sling group. There was no significant difference between the groups regarding the Constant-Murley scores at three weeks, six months, and one year. The shoulder forward flexion angle was significantly lower in the nonsling group on the 45<sup>th</sup> day. There was no significant difference between the three groups in respect of the shoulder forward flexion at three months, six months, and one year.

**Conclusion:** No difference was determined between the groups at the six-month and one-year functional results. Not using a sling bandage can be recommended by reducing pain in the early postoperative period.

**Keywords:** Postoperative rehabilitation, rotator cuff tear, sling bandages, sling bandages with an abduction pillow.

Rotator cuff tears are common causes of shoulder pain and dysfunction.<sup>[1,2]</sup> The aim of rotator cuff repair and combined rehabilitation is to reduce pain and improve quality of life, increase active and passive range of motion, and increase strength and endurance.<sup>[1,3,4]</sup> Arthroscopic repair of rotator cuff tears is a very common surgical method. Stiffness, although less common after open repair, is the most common complication of arthroscopic rotator cuff surgery.<sup>[5]</sup>

In the first four to six weeks after arthroscopic surgery, patients are recommended to wear a brace or sling to refrain from physical activities.<sup>[6-10]</sup> However, immobilization leads to some negative effects on the shoulder, including muscle atrophy, joint adhesions, and tendon degradation.<sup>[11,12]</sup> There is still no consensus on retear rates between immobilization and early passive motion. Moreover, long-term immobilization causes more pain, functional restriction, and delayed recovery and return to work.<sup>[10,13-16]</sup> The discussion is

**Corresponding author:** Yavuz Şahbat, MD. Mareşal Çakmak Askeri Hastanesi, Ortopedik Cerrahi ve Travmatoloji Kliniđi, 25070 Palandöken, Erzurum, Türkiye.

**E-mail:** yavuzsahbat@gmail.com

**Received:** March 13, 2023 **Accepted:** January 27, 2024 **Published online:** October 31, 2024

**Cite this article as:** Pepe İM, Şahbat Y, Çalıřal E, Yılmaz S, Topcuođlu İA, Aracı A, Erdođanođlu Y. Is it necessary to use a sling or abduction pillow sling after superior rotator cuff repair? A preliminary report. Turk J Phys Med Rehab 2024;70(x):i-ix. doi: 10.5606/tftrd.2024.12653.



still ongoing about immobilizing the shoulder joint for a certain period or initiating movement in the early period after arthroscopic repair of a shoulder rotator cuff tear.

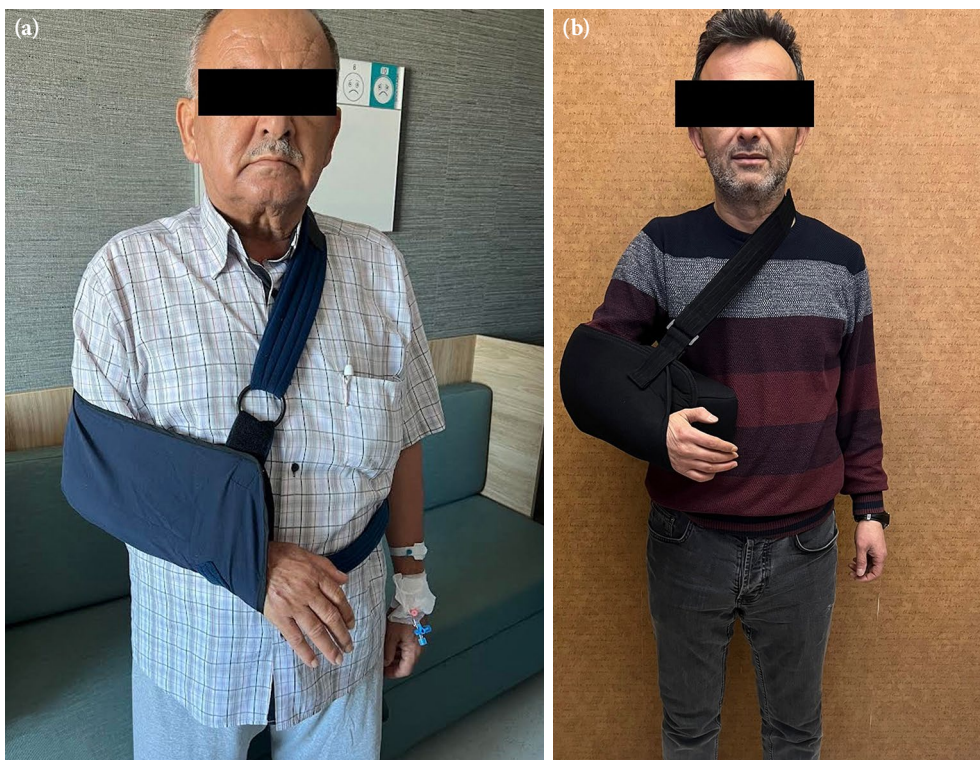Abduction pillow sling is the presence of a pillow between the patient's arm and thorax and keeps the shoulder in an abduction position of 30 to 45° relative to the normal arm sling. Some authors advocate using the shoulder abduction brace since it reduces tension and gap formation in the supraspinatus repair area, increases blood supply, and thus causes less pain and faster tendon-bone union.<sup>[17,18]</sup> However, there are also studies mentioning that an abduction brace has no effect on clinical score, pain level, and healing.<sup>[19]</sup> During the immobilization period, while surgeons from the USA commonly use an abduction pillow sling, European surgeons prefer a simple sling to ensure immobilization of the shoulder.<sup>[20]</sup> There are very few randomized controlled studies in the literature comparing pain and function between immobilization or early passive motion with an arm sling, and there are no studies comparing the use of an abduction pillow sling with immobilization.<sup>[11]</sup> Hence, this study aimed to evaluate the effect of using a shoulder sling, using a shoulder sling with a pillow, or not using a

sling effect the shoulder functional score and pain levels following arthroscopic rotator cuff tear repair.

## PATIENTS AND METHODS

This prospective randomized clinical trial was conducted with 90 patients (49 males, 41 females; mean age: 56.2±12.2 year; range, 33 to 77 years) at the ?...? between July 2020 and October 2022. Patients with a small-to-mid (<3 cm), full-thickness superior rotator cuff tear based on the DeOrto and Cofield<sup>[21]</sup> classification were included in the study. All patients underwent arthroscopic double-row repair in the beach chair position, performed by an expert surgeon. Exclusion criteria were as follows: (i) large, massive, and Patte type 2 and 3 retracted tears,<sup>[22]</sup> (ii) Goutallier type 3 or 4 fatty atrophy,<sup>[23]</sup> (iii) previous trauma, infection, or surgery of the same upper extremity, and (iv) those who could not adapt to the postoperative rehabilitation program.

Patients were randomly separated into three groups using an online randomization software (<http://www.graphpad.com/quickcalcs/index.cfm>). The patients in the nonsling group (n=28) wore no sling, those in the sling group (n=32) wore sling



**Figure 1.** (a) Sling bandages with no pillow. (b) Sling bandages with an abduction pillow.

bandages, and those in the abduction pillow sling group (n=30) wore sling bandages with an abduction pillow (Figure 1).

### Surgical technique

All arthroscopic surgeries were performed by an experienced surgeon with the patient in the beach chair position under general anesthesia. The greater tuberosity was debrided, and a suture anchor (3.5 mm) was placed at the bone-cartilage junction. Medial row sutures were passed through the rotator cuff tendon and knotted. The lateral row fixation was performed using a peek anchor. Acromioplasty was performed in cases with a positive impingement test and radiographic sign; the presence of spur formation was determined intraoperatively. A biceps tenotomy was performed if the long head of the biceps tendon was detached from the superior labrum.

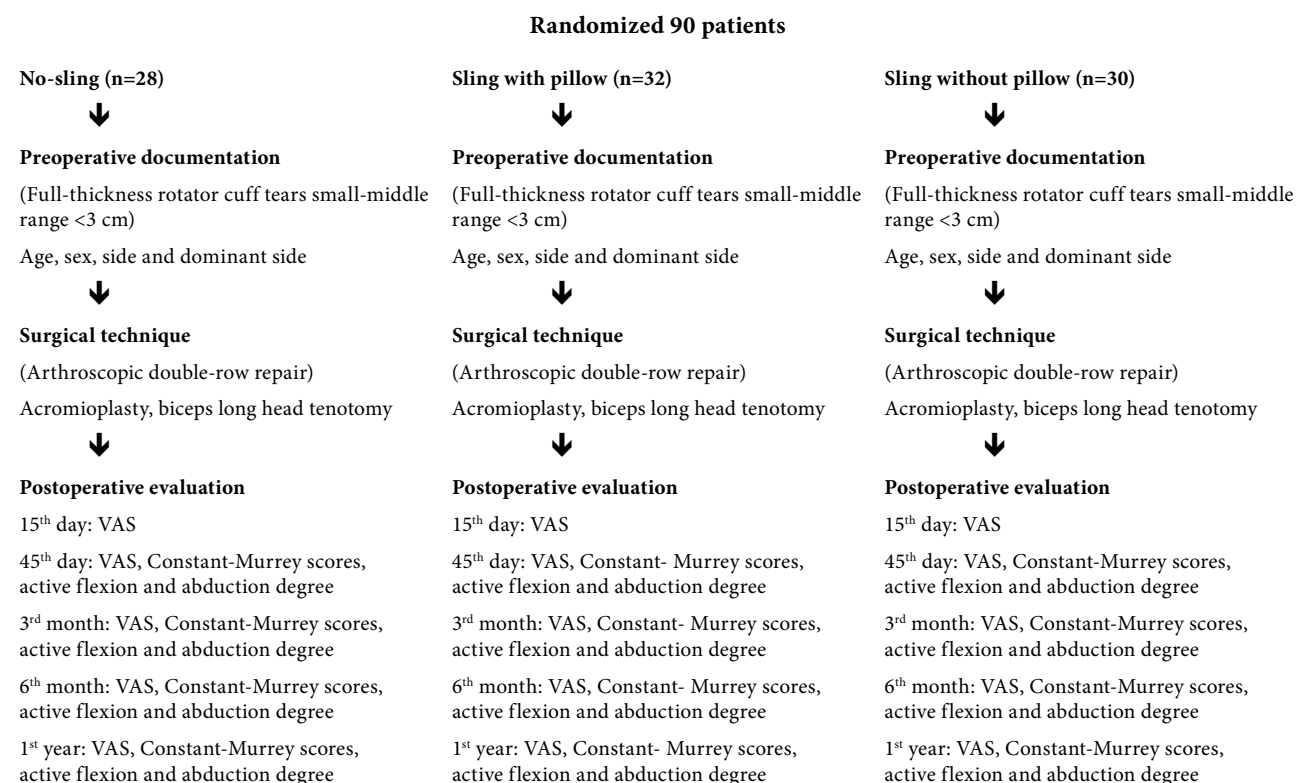
It was recorded if the biceps procedure (tenotomy) and acromioplasty were applied.<sup>[24,25]</sup> Peripheral block was not applied to any patient before or after the operation. At the end of the operation, the arm sling and abduction pillow sling were applied to the patients in the sling and abduction pillow sling

groups while the patient was still in the beach chair position.

### Postoperative rehabilitation and follow-up

In all patients who were followed up with a sling or abduction pillow sling, the arm was immobilized by fixation to the body with a sling for the first four weeks. In the nonsling group, the arm was not immobilized with a sling for the first four weeks, but active mobilization and weight-bearing were not allowed. A similar pendulum (passive range of motion) exercise program was organized for all three groups in the first four weeks.<sup>[26]</sup> All the patients performed the self-mobilization pendulum exercises four times a day for 10 min. It was confirmed that all the patients followed the surgeon's recommendations during the ambulatory clinic controls. After the patients were discharged from the hospital, they were reminded of the exercises with a weekly telephone call. The arm slings were terminated at the end of the fourth postoperative week.

Active motion was started after the fourth postoperative week, and the same rehabilitation program was applied to all the groups from fourth to



**Figure 2.** Consolidated standards of reporting trials flow diagram.

VAS: Visual Analog Scale.

10<sup>th</sup> postoperative weeks.<sup>[27]</sup> Continuous passive ROM and active assisted ROM exercises were performed for all groups in this period.<sup>[26]</sup> All three groups were permitted to return to daily living activities and light sports after two months.

The strengthening program was started by the same physiotherapist team within the same program for all patients between weeks 10 and 16.<sup>[26]</sup> The advanced strengthening program (abduction utilizing elastic resistance bands) was started for all patients after the 16<sup>th</sup> week.<sup>[26]</sup>

Age, sex, affected side, dominant side, whether a biceps procedure was performed, or if an acromioplasty was undertaken was recorded. The Visual Analog Scale (VAS) pain scores were recorded preoperatively, on the postoperative 15<sup>th</sup> and 45<sup>th</sup> days, and at the end of the third month, sixth month, and first year. The VAS scale ranges from 0 to 10. A score of 0 indicates no pain, and 10 indicates the worst possible pain.<sup>[28]</sup> Shoulder Constant-Murley scores and degrees of anterior forward flexion and abduction were recorded preoperatively, on the 45<sup>th</sup> day, at three months, six months, and one year postoperatively. Constant-Murley score is a 100-point scale that consists of four parameters: shoulder pain, range of motion, shoulder strength, and activities of daily living. A higher score indicates better results

(Figure 2).<sup>[29]</sup> Shoulder anterior forward flexion and abduction degrees were measured with a 12-inch goniometer while the patient's back was against the wall.<sup>[30]</sup>

### Statistical analysis

Power analyses were performed using the G\*power version 3.9.1 (Heinrich-Heine-Universität Düsseldorf, Düsseldorf, Germany). The primary hypothesis for sample size calculation was detecting the difference between groups. The required sample size was estimated with an effect size of 0.5, an alpha of 0.05, and a power of 0.8.<sup>[31,32]</sup> The required sample size for one group was calculated as 27 for 80% actual power.

The statistical analysis was performed using IBM SPSS version 26.0 software (IBM Corp., Armonk, NY, USA). The Kolmogorov-Smirnov test was used to determine the normality of the variables. Descriptive data were expressed in mean  $\pm$  standard deviation (SD) for continuous variables and in number and frequency for categorical variables. The Pearson chi-square test and Fisher exact test were used to compare categorical data between groups. The Kruskal-Wallis H test (Mann-Whitney U test with post hoc Bonferroni correction) or one-way analysis of variance (post hoc Bonferroni) were used, depending on the distribution pattern. The level of statistical significance was accepted as  $p < 0.05$ .

**TABLE 1**  
Characteristic of participants and surgical procedure

	No-sling			Sling with pillow			Sling without pillow			p
	n	%	Mean $\pm$ SD	n	%	Mean $\pm$ SD	n	%	Mean $\pm$ SD	
Age (year)			56.4 $\pm$ 11.5			57.0 $\pm$ 13.4			55.5 $\pm$ 12.2	0.895 <sup>c</sup>
Sex										0.850 <sup>c</sup>
Male	14	50		18	56.3		17	56.7		
Female	14	50		14	43.8		13	43.3		
Side										0.660 <sup>a</sup>
Right	19	67.9		20	62.5		22	73.3		
Left	9	32.1		12	37.5		8	26.7		
Dominant side										1.000 <sup>b</sup>
Right	24	85.7		27	84.4		26	86.7		
Left	4	14.3		5	15.6		4	13.3		
Biceps long head procedure										0.660 <sup>a</sup>
None	12	42.9		17	53.1		16	53.3		
Tenotomy	16	57.1		15	46.9		14	46.7		
Acromioplasty										0.591 <sup>a</sup>
None	14	50		18	56.3		19	63.3		
Yes	14	50		14	43.8		11	36.7		

SD: Standard deviation; a: Pearson chi-square; b: Fisher exact test; c: Independent sample t-test.

## RESULTS

There was no statistical difference between the groups in terms of age, sex, affected side, dominant side, biceps procedure, or acromioplasty (Table 1). There was no significant difference between the groups in the VAS scores before and after the operation on the 45<sup>th</sup> day and at three months, six months, and one year. On the 15<sup>th</sup> postoperative day, the VAS score was found to be significantly lower in the nonsling group (7.6±1.3) compared to the groups using a sling (8.4±1.1) and abduction pillow sling (8.5±1.2;  $p=0.023$ , Table 2).

In the Bonferroni-corrected Mann-Whitney U test conducted to determine the origin of the differences among groups, the VAS scores on the 15<sup>th</sup> day for the nonsling group were found to be statistically significantly different from those of the other groups ( $p<0.0167$ ).

There was no significant difference between the groups in the shoulder Constant-Murley scores before and after the operation at three and six months. On

the 45<sup>th</sup> day, the shoulder Constant-Murley score was found to be significantly higher in the abduction pillow sling group (54.4±14.7) than in the nonsling group (44.1±15.5;  $p=0.035$ , Table 3).

In the Bonferroni-corrected Mann-Whitney U analysis performed to determine the source of differences among groups, the nonsling group showed statistically significant differences compared to the sling and abduction pillow sling groups in the Constant-Murley (CS) score on the 45<sup>th</sup> day ( $p<0.0167$ ).

The shoulder anterior forward flexion angle was significantly lower in the nonsling group (103.25±26.21) on the 45<sup>th</sup> day compared to the sling (135.27±20.61) and abduction pillow sling groups (131.44±28.53;  $p<0.000$ ).

There was no significant difference between the three groups in respect of shoulder anterior forward flexion at three months, six months, and one year (Table 4). There was no significant difference between the groups in respect of shoulder abduction (Table 5).

**TABLE 2**  
Evaluation of VAS scores between groups

VAS pain score	No sling	Sling with pillow	Sling without pillow	<i>p</i>	Difference
	Mean±SD	Mean±SD	Mean±SD		
Preoperative	8.1±1.5	8.7±1.6	8.8±1.2	0.265 <sup>a</sup>	
15 <sup>th</sup> day	7.6±1.3	8.5±1.2	8.4±1.1	<b>0.008<sup>a</sup></b>	1<2,3*
45 <sup>th</sup> day	6.5±1.5	5.8±1.9	6.6±0.8	0.183 <sup>a</sup>	
Postoperative					
3 <sup>rd</sup> month	4.2±1	3.9±1.3	4.6±1	0.064 <sup>a</sup>	
6 <sup>th</sup> month	2.1±1.2	1.9±1.3	2.7±1.3	0.077 <sup>a</sup>	
1 <sup>st</sup> year	1.9±1.3	1.8±1.1	2.2±1.1	0.092 <sup>a</sup>	

VAS: Visual Analog Scale; SD: Standard deviation; a: Kruskal Wallis H-test; \* In the Bonferroni-corrected Mann-Whitney U analysis conducted to determine the origin of the differences among groups, the VAS scores on the 15<sup>th</sup> day for the nonsling group was found to be statistically significantly different from those of the other groups ( $p<0.0167$ ).

**TABLE 3**  
Evaluation of Shoulder constant scores between groups

Shoulder constant score	No sling	Sling with pillow	Sling without pillow	<i>p</i>	Difference
	Mean±SD	Mean±SD	Mean±SD		
Preoperative	40.54±14.24	39.75±15	38.77±11.06	0.883 <sup>a</sup>	
45 <sup>th</sup> day	44.11±15.54	54.41±14.72	52.2±12.97	0.012‡	1<2*
Postoperative					
3 <sup>rd</sup> month	75.25±13.14	75.75±13.99	72.33±12.87	0.563 <sup>a</sup>	
6 <sup>th</sup> month	88.25±9.08	89 ±7.88	86.17±8.65	0.390‡	
1 <sup>st</sup> year	90.34±1.03	91±9.92	90.20±4.28	0.321 <sup>a</sup>	

SD: Standard deviation; a: One way ANOVA; ‡ Kruskal Wallis H-test; \* In the Bonferroni-corrected Mann-Whitney U analysis performed to determine the source of differences among groups, the nonsling group showed statistically significant differences from the sling and abduction pillow sling groups in the Constant-Murley score on the 45<sup>th</sup> day ( $p<0.0167$ ).

TABLE 4 Evaluation of shoulder forward flexion angles between groups					
Shoulder forward flexion	No sling	Sling with pillow	Sling without pillow	<i>p</i>	Difference
	Mean±SD	Mean±SD	Mean±SD		
Preoperative	105.93±24.58	117.47±37.65	122.4±22.67	0.098 <sup>a</sup>	
45 <sup>th</sup> day	103.25±26.21	131.44±28.53	135.27±20.61	<0.001‡	1<2,3*
Postoperative					
3 <sup>rd</sup> month	135.07±25.46	148.88±22.43	153.4±15.93	0.005‡	1<3*
6 <sup>th</sup> month	160.39±19.85	166.28±12.67	167.07±12.62	0.198‡	
1 <sup>st</sup> year	165.91±17.43	167.55±14.59	167.5±14.79	0.175‡	

SD: Standard deviation; a: One way ANOVA, ‡ Kruskal-Wallis H test; \* The Bonferroni-corrected Mann-Whitney U analysis revealed statistically significant differences in the nonsling group compared to the other groups on the 45<sup>th</sup> day, as well as between the nonsling group and the sling group at three months (*p*<0.0167).

TABLE 5 Evaluation of shoulder abduction angles between groups				
Shoulder abduction	No sling	Sling with pillow	Sling without pillow	<i>p</i>
	Mean±SD	Mean±SD	Mean±SD	
Preoperative	85.86±24.8	82.34±26.7	81.23±22.84	0.900‡
45 <sup>th</sup> day	85±20.29	92.03±20.03	91.07±18.19	0.408‡
Postoperative				
3 <sup>rd</sup> month	120.46±21.94	121±21.07	114.7±19.42	0.430 <sup>a</sup>
6 <sup>th</sup> month	141.07±19.31	148.66±13.97	139.37±20.31	0.079‡
1 <sup>st</sup> year	151.09±17.11	152.68±11.7	149.4±12.98	0.301 <sup>a</sup>

SD: Standard deviation; a: One-way analysis of variance; ‡ Kruskal-Wallis H test.

## DISCUSSION

The most important findings of the current study were that no difference was determined between the groups with respect to the pain scores and functional results at the six-month follow-up examination. There was also no significant difference in the clinical results of nonsling, immobilization with a sling, and immobilization with an abduction pillow sling in patients who underwent arthroscopic double-row repair. No significant difference was determined between the groups in the VAS scores before and after the operation on the 45<sup>th</sup> day and at three months, six months, and one year. According to our data, suggesting the use of an arm sling to alleviate pain might be considered incorrect since arm slings are not proven to reduce pain. This may be due to glenohumeral capsular contracture or elbow immobility; however, further studies are needed. The present study is the first to have compared the use of an abduction pillow sling with other immobilization or early movement techniques. Since the functional outcome will be similar by the sixth month and first year postoperatively, nonsling rehabilitation can be recommended only to reduce pain in the early

postoperative period. Physicians can use all three rehabilitation protocols with confidence.

The exercise programs given after arthroscopic rotator cuff repair are mostly based on surgical and clinical experience.<sup>[13]</sup> There is no consensus on the optimal rehabilitation after rotator cuff repair.<sup>[20]</sup> Some authors advocate six to eight weeks of immobilization to accelerate tissue healing and reduce retear, while others have stated that early mobilization is associated with greater range of motion and better functional outcomes.<sup>[10,13,33,34]</sup> Tirefort et al.<sup>[11]</sup> reported that no immobilization after superior rotator cuff repair is associated with better early mobility and functional scores in comparison with sling immobilization. However, Tirefort et al.<sup>[11]</sup> reported that while there was a difference in anterior forward flexion and abduction in the first month, this difference disappeared in the following months. In contrast, although no difference in pain was observed during the initial months, a variation was identified in the sixth month in Tirefort et al.'s study. Therefore, we considered whether the use of an arm sling in the fourth week affected pain in the sixth month. In the current study, no difference was determined between

the groups in terms of pain and function after the third month. Nonsling rehabilitation was effective in reducing pain only in the first months. In addition, the sling bandages with an abduction pillow had the same results as the simple arm sling.

It is believed that partial rotator cuff tears create a predisposition to full-thickness rotator cuff tears by causing damage to the surrounding tissues.<sup>[23]</sup> Gimbel et al.<sup>[35]</sup> reported that tendon and bone healing increased after movement restriction in the shoulders of rats, and it contributed positively to collagen fiber resistance and organization. Similarly, in another rat model study, Peltz et al.<sup>[36]</sup> reported that early movement is harmful to shoulder biomechanics and tissue healing. In contrast, Klintberg et al.<sup>[3]</sup> argued that exercise and movement are necessary for adequate recovery of tendons after surgery and that it is necessary to initiate movement in the proliferative phase of recovery. However, in the current study, retear was not investigated as a routine protocol.

One of the most important purposes of surgical repair of a rotator cuff tear is to enable patients to perform their daily activities painlessly and comfortably and to return to their work life with the desired performance.<sup>[37]</sup> Therefore, for selected suitable patients, some authors have suggested intensive early rehabilitation by increasing the range of motion of the joint to improve quality of life.<sup>[38-40]</sup> Some authors have argued that early immobilization may cause delayed recovery, more pain, and functional limitations.<sup>[13,15,16]</sup> A strong aspect that differentiates this study from previous research is that it was a randomized study in which three groups were homogeneously separated, and all the operations were performed by a single surgeon. There have been developments in rehabilitation protocols, and the combined surgical repair techniques and rehabilitation protocols have increased, which has led to increased implementation of early rehabilitation, particularly in the treatment of Achilles tendon ruptures, flexor tendon injuries, and shoulder rotator cuff tears.<sup>[41,42]</sup>

The main limitation of this study, as well as previous studies<sup>[11,43]</sup> in this field, is that only small- and medium-sized rotator cuff tears have been evaluated. The probable reason why no studies have examined large tears is that doctors still believe large tears need stabilization after repair. Therefore, this can be considered a substantial bias. The other limitation of this study was that tendon healing was not evaluated radiologically.

In conclusion, no significant difference in range of motion or functional difference was observed at six-month and one-year follow-ups of patients with four weeks of immobilization with a sling, immobilization with an abduction pillow sling, or no use of a sling. Therefore, immobilization with a sling or abduction pillow sling may not be necessary after arthroscopic repair of small or moderate tears. According to our data, mobilization without a sling has shown better pain reduction. Therefore, the authors recommend nonsling mobilization as the first option for small or moderate tears.

**Ethics Committee Approval:** The study protocol was approved by the Alanya Alaaddin Keykubat University Faculty of Medicine Clinical Research Ethics Committee (date: 18.06.2020, no: 18.06.2020/20-6). The study was conducted in accordance with the principles of the Declaration of Helsinki.

**Patient Consent for Publication:** A written informed consent was obtained from each patient.

**Data Sharing Statement:** The data that support the findings of this study are available from the corresponding author upon reasonable request.

**Author Contributions:** Concept: Y.S., İ.M.P., A.A.; Design: İ.M.P., Y.E., İ.A.T.; Supervision: E.Ç., Y.S.; Materials: İ.A.T., İ.M.P., A.A.; Data collection and/or processing: İ.M.P., Y.S., E.Ç., S.Y., Y.E.; Analysis and interpretation: Y.Ş., Y.E., İ.M.P.; Literature review: Y.Ş., E.Ç., İ.M.P., S.Y.; Writing manuscript: Y.S., İ.M.P., Y.E.; Critical reviews: Y.Ş., İ.M.P., S.Y.

**Conflict of Interest:** The authors declared no conflicts of interest with respect to the authorship and/or publication of this article.

**Funding:** The authors received no financial support for the research and/or authorship of this article.

## REFERENCES

1. Chan K, MacDermid JC, Hoppe DJ, Ayeni OR, Bhandari M, Foote CJ, et al. Delayed versus early motion after arthroscopic rotator cuff repair: A meta-analysis. *J Shoulder Elbow Surg* 2014;23:1631-9. doi: 10.1016/j.jse.2014.05.021.
2. Chung SW, Huong CB, Kim SH, Oh JH. Shoulder stiffness after rotator cuff repair: Risk factors and influence on outcome. *Arthroscopy* 2013;29:290-300. doi: 10.1016/j.arthro.2012.08.023.
3. Klintberg IH, Gunnarsson AC, Svantesson U, Styf J, Karlsson J. Early loading in physiotherapy treatment after full-thickness rotator cuff repair: A prospective randomized pilot-study with a two-year follow-up. *Clin Rehabil* 2009;23:622-38. doi: 10.1177/0269215509102952.
4. Rokito AS, Zuckerman JD, Gallagher MA, Cuomo F. Strength after surgical repair of the rotator cuff. *J Shoulder Elbow Surg* 1996;5:12-7. doi: 10.1016/s1058-2746(96)80025-5.

5. Brislin KJ, Field LD, Savoie FH 3rd. Complications after arthroscopic rotator cuff repair. *Arthroscopy* 2007;23:124-8. doi: 10.1016/j.arthro.2006.09.001.
6. Acevedo DC, Paxton ES, Williams GR, Abboud JA. A survey of expert opinion regarding rotator cuff repair. *J Bone Joint Surg Am* 2014;96:e123. doi: 10.2106/JBJS.M.00399.
7. Gumina S, Candela V, Passaretti D, Mariani L, Orsina L. Does immobilization position after arthroscopic rotator cuff repair impact work quality or comfort? *Musculoskelet Surg* 2014;98 Suppl 1:55-9. doi: 10.1007/s12306-014-0327-y.
8. Keener JD, Galatz LM, Stobbs-Cucchi G, Patton R, Yamaguchi K. Rehabilitation following arthroscopic rotator cuff repair: A prospective randomized trial of immobilization compared with early motion. *J Bone Joint Surg [Am]* 2014;96:11-9. doi: 10.2106/JBJS.M.00034.
9. Lo IK, Burkhart SS. Transtendon arthroscopic repair of partial-thickness, articular surface tears of the rotator cuff. *Arthroscopy* 2004;20:214-20. doi: 10.1016/j.arthro.2003.11.042.
10. Mazuquin BF, Wright AC, Russell S, Monga P, Selfe J, Richards J. Effectiveness of early compared with conservative rehabilitation for patients having rotator cuff repair surgery: An overview of systematic reviews. *Br J Sports Med* 2018;52:111-21. doi: 10.1136/bjsports-2016-095963.
11. Tirefort J, Schwitzgubel AJ, Collin P, Nowak A, Plomb-Holmes C, Lädermann A. Postoperative mobilization after superior rotator cuff repair: Sling versus no sling: A randomized prospective study. *J Bone Joint Surg Am* 2019;101:494-503. doi: 10.2106/JBJS.18.00773.
12. Valkering KP, Aufwerber S, Ranuccio F, Lunini E, Edman G, Ackermann PW. Functional weight-bearing mobilization after Achilles tendon rupture enhances early healing response: A single-blinded randomized controlled trial. *Knee Surg Sports Traumatol Arthrosc* 2017;25:1807-16. doi: 10.1007/s00167-016-4270-3.
13. Mazzocca AD, Arciero RA, Shea KP, Apostolakis JM, Solovyova O, Gomlinski G, et al. The effect of early range of motion on quality of life, clinical outcome, and repair integrity after arthroscopic rotator cuff repair. *Arthroscopy* 2017;33:1138-48. doi: 10.1016/j.arthro.2016.10.017.
14. Sonoda Y, Nishioka T, Nakajima R, Imai S, Vigers P, Kawasaki T. Use of a shoulder abduction brace after arthroscopic rotator cuff repair: A study on gait performance and falls. *Prosthet Orthot Int* 2018;42:136-43. doi: 10.1177/0309364617695882.
15. Houck DA, Kraeutler MJ, Schuette HB, McCarty EC, Bravman JT. Early versus delayed motion after rotator cuff repair: A systematic review of overlapping meta-analyses. *Am J Sports Med* 2017;45:2911-5. doi: 10.1177/0363546517692543.
16. Namdari S, Green A. Range of motion limitation after rotator cuff repair. *J Shoulder Elbow Surg* 2010;19:290-6. doi: 10.1016/j.jse.2009.07.009.
17. Hawthorne JR, Carpenter EM, Lam PH, Murrell GAC. Effects of abduction pillows on rotator cuff repair: A biomechanical analysis. *HSS J* 2018;14:114-22. doi: 10.1007/s11420-017-9592-2.
18. Andres BM, Lam PH, Murrell GA. Tension, abduction, and surgical technique affect footprint compression after rotator cuff repair in an ovine model. *J Shoulder Elbow Surg* 2010;19:1018-27. doi: 10.1016/j.jse.2010.04.005.
19. Pandey V, Madi S, Maddukuri S, Acharya K, Karegowda LH, Willems WJ. Does application of abduction brace after arthroscopic rotator cuff repair improve blood flow around posterosuperior rotator cuff and repair site, affecting pain levels and clinical and structural outcomes? A pilot randomized controlled trial. *JSES Int* 2020;4:848-59. doi: 10.1016/j.jseint.2020.07.021.
20. Freehill MT, Murray IR, Calvo E, Lädermann A, Srikumaran U. Shoulder surgery postoperative immobilization: An international survey of shoulder surgeons. *Biology (Basel)* 2023;12:291. doi: 10.3390/biology12020291.
21. DeOrio JK, Cofield RH. Results of a second attempt at surgical repair of a failed initial rotator-cuff repair. *J Bone Joint Surg [Am]* 1984;66:563-7.
22. Patte D. Classification of rotator cuff lesions. *Clin Orthop Relat Res* 1990;254:81-6.
23. Goutallier D, Postel JM, Bernageau J, Lavau L, Voisin MC. Fatty muscle degeneration in cuff ruptures. Pre- and postoperative evaluation by CT scan. *Clin Orthop Relat Res* 1994;304:78-83.
24. Cunningham G, Lädermann A. Tendon of the long head of the biceps brachii: Tenotomy versus tenodesis? *Lead Opin Orthop Rheumatol* 2011;2:16-18.
25. Charbonnier C, Chagué S, Kevelham B, Preissmann D, Kolo FC, Rime O, et al. ArthroPlanner: A surgical planning solution for acromioplasty. *Int J Comput Assist Radiol Surg* 2018;13:2009-19. doi: 10.1007/s11548-018-1707-9.
26. Nikolaidou O, Migkou S, Karampalis C. Rehabilitation after rotator cuff repair. *Open Orthop J* 2017;11:154-62. doi: 10.2174/1874325001711010154.
27. Thigpen CA, Shaffer MA, Gaunt BW, Leggin BG, Williams GR, Wilcox RB 3rd. The American Society of Shoulder and Elbow Therapists' consensus statement on rehabilitation following arthroscopic rotator cuff repair. *J Shoulder Elbow Surg* 2016;25:521-35. doi: 10.1016/j.jse.2015.12.018.
28. Boonstra AM, Schiphorst Preuper HR, Reneman MF, Posthumus JB, Stewart RE. Reliability and validity of the visual analogue scale for disability in patients with chronic musculoskeletal pain. *Int J Rehabil Res* 2008;31:165-9. doi: 10.1097/MRR.0b013e3282fc0f93.
29. Vrotsou K, Ávila M, Machón M, Mateo-Abad M, Pardo Y, Garin O, et al. Constant-murley score: Systematic review and standardized evaluation in different shoulder pathologies. *Qual Life Res* 2018;27:2217-26. doi: 10.1007/s11136-018-1875-7.
30. Gajdosik RL, Bohannon RW. Clinical measurement of range of motion. Review of goniometry emphasizing reliability and validity. *Phys Ther* 1987;67:1867-72. doi: 10.1093/ptj/67.12.1867.
31. Pepe M, Calisal E, Kocadal O, Bicer E, Taskin S, Aktekin CN. The role of surgical closure position in total knee arthroplasty: Flexion versus extension-a randomized prospective study. *J Knee Surg* 2019;32:624-9. doi: 10.1055/s-0038-1666865.
32. Aksahin E, Aktekin CN, Kocadal O, Duran S, Gunay C, Kaya D, et al. Sagittal plane tilting deformity of the patellofemoral joint: A new concept in patients with



- chondromalacia patella. *Knee Surg Sports Traumatol Arthrosc* 2017;25:3038-45. doi: 10.1007/s00167-016-4083-4.
33. Denard PJ, Lädermann A, Burkhart SS. Prevention and management of stiffness after arthroscopic rotator cuff repair: Systematic review and implications for rotator cuff healing. *Arthroscopy* 2011;27:842-8. doi: 10.1016/j.arthro.2011.01.013.
34. Saltzman BM, Zuke WA, Go B, Mascarenhas R, Verma NN, Cole BJ, et al. Does early motion lead to a higher failure rate or better outcomes after arthroscopic rotator cuff repair? A systematic review of overlapping meta-analyses. *J Shoulder Elbow Surg* 2017;26:1681-91. doi: 10.1016/j.jse.2017.04.004.
35. Gimbel JA, Van Kleunen JP, Williams GR, Thomopoulos S, Soslowky LJ. Long durations of immobilization in the rat result in enhanced mechanical properties of the healing supraspinatus tendon insertion site. *J Biomech Eng* 2007;129:400-4. doi: 10.1115/1.2721075.
36. Peltz CD, Dourte LM, Kuntz AF, Sarver JJ, Kim SY, Williams GR, et al. The effect of postoperative passive motion on rotator cuff healing in a rat model. *J Bone Joint Surg Am* 2009;91:2421-9. doi: 10.2106/JBJS.H.01121.
37. Parsons BO, Gruson KI, Chen DD, Harrison AK, Gladstone J, Flatow EL. Does slower rehabilitation after arthroscopic rotator cuff repair lead to long-term stiffness? *J Shoulder Elbow Surg* 2010;19:1034-9. doi: 10.1016/j.jse.2010.04.006.
38. Gallagher BP, Bishop ME, Tjoumakaris FP, Freedman KB. Early versus delayed rehabilitation following arthroscopic rotator cuff repair: A systematic review. *Phys Sportsmed* 2015;43:178-87. doi: 10.1080/00913847.2015.1025683.
39. Ross D, Maerz T, Lynch J, Norris S, Baker K, Anderson K. Rehabilitation following arthroscopic rotator cuff repair: A review of current literature. *J Am Acad Orthop Surg* 2014;22:1-9. doi: 10.5435/JAAOS-22-01-1.
40. Sgroi TA, Cilenti M. Rotator cuff repair: Post-operative rehabilitation concepts. *Curr Rev Musculoskelet Med* 2018;11:86-91. doi: 10.1007/s12178-018-9462-7.
41. Kauwe M. Acute achilles tendon rupture: Clinical evaluation, conservative management, and early active rehabilitation. *Clin Podiatr Med Surg* 2017;34:229-43. doi: 10.1016/j.cpm.2016.10.009.
42. Giesen T, Calcagni M, Elliot D. Primary flexor tendon repair with early active motion: Experience in Europe. *Hand Clin* 2017;33:465-72. doi: 10.1016/j.hcl.2017.03.001.
43. Misir A, Oguzkaya S, Kizkapan TB, Eken G, Sayer G. The effect of postoperative sling immobilization and early mobilization on clinical and functional outcomes after arthroscopic rotator cuff repair: A propensity score-matched analysis. *J Back Musculoskelet Rehabil* 2022;35:1391-8. doi: 10.3233/BMR-210358.