

## Inadvertent intradiscal flow during transforaminal epidural steroid injection

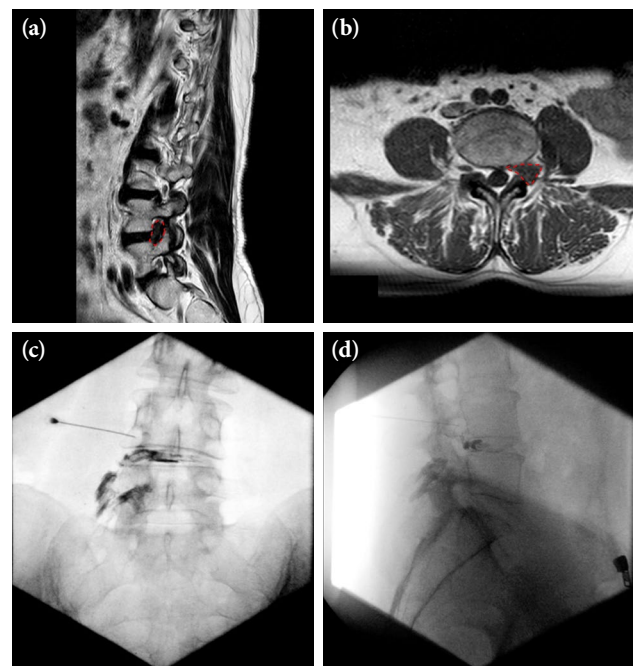
Merve Sekizkardes Tutuncu , Savas Sencan , Serdar Kokar , Osman Hakan Gunduz

Department of Physical Medicine and Rehabilitation, Division of Pain Management, Marmara University Faculty of Medicine, Pendik Training and Research Hospital, İstanbul, Türkiye

A 52-year-old female patient presented with low back pain radiating toward the left lower extremity. Magnetic resonance imaging showed a foraminal extruded disc herniation with caudal migration at the L4-5 level with compression of the left L4 nerve root. Accordingly, a transforaminal epidural steroid injection (TFESI) was planned. The patient was prepared in a prone position and draped in a sterile fashion. A 22-gauge, 90-mm Quincke spinal needle (Global Medikit Limited, Uttarakhand, India) was advanced toward the safe triangle beneath the pedicle under fluoroscopic visualization. The final needle position under the subpedicular area was confirmed after visualizing it in anteroposterior and lateral views. However, upon injecting contrast dye, an inadvertent intradiscal flow was noticed. Prophylactic intravenous cephazolin was administered. No adverse reaction, such as discitis, was encountered in the long-term follow-up. A written informed consent was obtained from the patient.

Transforaminal epidural steroid injection is one of the most commonly used interventional procedures for managing lumbar radicular pain resulting from lumbar spinal stenosis, degenerative discogenic disease, or failed back surgery syndrome. Providing a high concentration of medication to the ventral epidural space is a crucial therapeutic advantage of TFESI.<sup>[1]</sup> However, the procedure has several risks, such as spinal cord infarction, paraplegia possibly due to intravascular injection, and intradiscal injection, which may be followed by discitis.

Candido et al.<sup>[2]</sup> and Plastaras et al.<sup>[3]</sup> provided an overall incidence of inadvertent intradiscal injection of 0.25 and 0.17%, respectively. Hong et al.,<sup>[4]</sup> on the



**Figure 1.** (a) Sagittal T2 view of magnetic resonance imaging demonstrates extruded disc material (red dashed line) filling up the left L4 foramen, and (b) the corresponding axial T1 image of the extruded disc (red dashed line) at the foraminal level. (c) Anteroposterior and (d) lateral fluoroscopic images of inadvertent intradiscal contrast spread during TFESI. Note the needle tip is correctly positioned in the neural foramen.

**Corresponding author:** Merve Sekizkardes Tutuncu, MD. Marmara Üniversitesi Tıp Fakültesi, Pendik Eğitim ve Araştırma Hastanesi, Fiziksel Tıp ve Rehabilitasyon Anabilim Dalı, Ağrı Yönetimi Bilim Dalı, 34899 Pendik, İstanbul, Türkiye.

**E-mail:** merve.sekizkardes@gmail.com

**Received:** November 12, 2023 **Accepted:** January 05, 2024 **Published online:** October 31, 2024

**Cite this article as:** Sekizkardes Tutuncu M, Sencan S, Kokar S, Gunduz OH. Inadvertent intradiscal flow during transforaminal epidural steroid injection. Turk J Phys Med Rehab 2024;70(4):557-558. doi: 10.5606/tftrd.2024.14243.



other hand, reported a much higher incidence of 2.3%. Considering that intradiscal injection during TFESI is not rare, clinicians need to be able to recognize this complication and take preventive steps. The most significant consequence following the inadvertent intradiscal flow of medication is discitis and, possibly, permanent neurological deficits.<sup>[3]</sup>

Inadvertent intradiscal injection has been attributed to several conditions: ipsilateral foraminal stenosis, far lateral disc herniation, and isthmic spondylolisthesis accompanied by protruded disc material into the intervertebral foramen. Moreover, according to Plataras et al.,<sup>[3]</sup> in the case of degenerative disc disease, a damaged annulus may contribute to the vacuum phenomenon and negative pressure of intradiscal space. This pressure gradient can pull the medication from the intended epidural space toward the intradiscal area.<sup>[4]</sup>

In conclusion, intradiscal injection during TFESI is not rare. Clinicians should be aware that even when the needle position has been confirmed, there is a chance of inadvertent intradiscal flow. Therefore, the authors believe it is crucial to know the potential risk factors, recognize the contrast pattern, and take preventive steps to minimize the risk of complications.

**Data Sharing Statement:** The data that support the findings of this study are available from the corresponding author upon reasonable request.

**Author Contributions:** All authors contributed equally to this article.

**Conflict of Interest:** The authors declared no conflicts of interest with respect to the authorship and/or publication of this article.

**Funding:** The authors received no financial support for the research and/or authorship of this article.

## REFERENCES

1. Sencan S, Celenlioglu AE, Yazici G, Gunduz OH. Transforaminal epidural steroid injection improves neuropathic pain in lumbar radiculopathy: A prospective, clinical study. *Neurol India* 2021;69:910-5. doi: 10.4103/0028-3886.323894.
2. Candido KD, Katz JA, Chinthagada M, McCarthy RA, Knezevic NN. Incidence of intradiscal injection during lumbar fluoroscopically guided transforaminal and interlaminar epidural steroid injections. *Anesth Analg* 2010;110:1464-1467. doi:10.1213/ANE.0b013e3181d6bd12.
3. Plataras CT, Casey E, Goodman BS, Chou L, Roth D, Rittenberg J. Inadvertent intradiscal contrast flow during lumbar transforaminal epidural steroid injections: A case series examining the prevalence of intradiscal injection as well as potential associated factors and adverse events. *Pain Med* 2010;11:1765-73. doi: 10.1111/j.1526-4637.2010.00943.x.
4. Hong JH, Kim SY, Huh B, Shin HH. Analysis of inadvertent intradiscal and intravascular injection during lumbar transforaminal epidural steroid injections: A prospective study. *Reg Anesth Pain Med* 2013;38:520-5. doi: 10.1097/AAP.0000000000000010.